

Iatrogenic Trauma to Gingiva – A Case Series

Ganesh, P.R

ABSTRACT

Background: Iatrogenic trauma is any traumatic injury inflicted by intervention, therapy or activity by a healthcare professional. The aim of this article is to present a series of rare traumatic lesions of the gingiva of iatrogenic etio-pathology. **Methods:** A total of nine cases of traumatic lesions of the gingiva due to ill-fitting orthodontic appliances or inappropriate orthodontic therapy are reported and their management by non-surgical periodontal therapy is discussed. **Results:** Orthodontic appliance therapy in addition to the effects on the periodontium has very rarely certain deleterious effects on the gingiva. The commonest of these manifestations is an inflammatory gingival enlargement. The management of these types of lesions involves elimination of the insult, motivation for personal oral hygiene maintenance, non surgical periodontal therapy and very rarely mucogingival surgery. **Conclusion:** Respect to the oral soft tissues, constant motivation of patients and adequate time spent on thorough examination during review visits prevent many iatrogenic insults to the tissues. Any orthodontic therapy requires the participation of a consultant Periodontist to manage the soft tissue problems which might arise from appliance wear.

Key words: Gingival injuries, Iatrogenic disease, Orthodontic Appliances, Adverse effects appliances, Non surgical periodontics.

INTRODUCTION

Traumatic gingival lesions of iatrogenic origin remain a rare entity with a minuscule number of reports in the literature.¹⁻³ This despite the recent AAP classification⁴ allocating a specific subcategory to these types of cases under the overall classification of non-plaque induced gingival lesions.⁵ The paucity of references on this topic, as determined from both published reviews and online literature search on Pub med and Medline, leads to the belief that the prevalence rate for such lesions is thankfully very low. The purpose of the current case series, is to present a series of cases where inadvertent iatrogenic injury coupled with the patients lack of proper personal oral hygiene through lapse of motivation, resulted in an entirely preventable lesion – an inflammatory gingival enlargement secondary to orthodontic therapy and predominantly localized to the anterior palatal region. The present case series includes patients who had reported to our private practice over a six month period beginning from September 2013, and currently being followed-up.

Case Reports

Case 1 – A female patient aged 16 years H/O tongue thrusting habit reported with an Inflammatory gingival enlargement of the Maxillary Anterior Palatal gingiva with BOP and pseudo-pockets due to fixed appliance with extra-long banded tongue spikes, rendering maintenance of proper oral hygiene almost impossible. Adequate debridement and prophylaxis

of the inflammatory tissues was done and gingiva restored to health by non-surgical therapy over the course of the following weeks. Patient was referred back to the orthodontic specialist with a suggestion to replace the tongue spikes with a more appropriate habit breaking appliance.

Case 2 – A female patient aged 19 years referred from the Orthodontics Specialist for generalized bleeding from the gingiva. Patient gave a history of six month orthodontic therapy with a bite raising removable appliance and on examination there was a marked inflammatory hyperplasia of the palatal anterior region which was subsequently successfully managed over the following weeks by non-surgical therapy before referring the patient back to the orthodontic specialist.

Case 3 - A female patient aged 22 years presented with a complaint of generalized bleeding from the gingiva. Patient gave a history of four months orthodontic therapy with a habit breaking removable appliance and on examination there was an inflammatory gingival enlargement of the anterior palatal region which was managed by non-surgical therapy successfully before referring the patient back to the orthodontic specialist.

Cases 4-9 – These cases were all referred from the various orthodontic clinics for management of inflammatory gingival enlargements secondary to appliance wear and were restored to health through non surgical therapy.

Ganesh, P.R

Dr. P.R. Ganesh¹ MDS Periodontics
¹Senior Assistant Professor,
Dept of Periodontics & Implantology
T. N. Government Dental College,
Chennai.

Correspondence

Dr. P. R. Ganesh MDS, F- 157,
5th Street, F-Block, Anna Nagar East,
Chennai-600102, INDIA.
Email: ganeshputtu@gmail.com
Phone: 9840136954

History

- Submission Date: 03-09-15;
- Review completed: 18-06-16;
- Accepted Date: 22-06-16.

DOI : 10.5530/BEMS.2016.1.5

Article Available online

<http://www.bemsreports.org>

Copyright

© 2016 Phcog.Net. This is an open-access article distributed under the terms of the Creative Commons Attribution 4.0 International license.

Cite this article : Ganesh PR. Iatrogenic trauma to Gingiva – A Case Series. BEMS Reports, 2016; 2(1):23-6.

Case -1

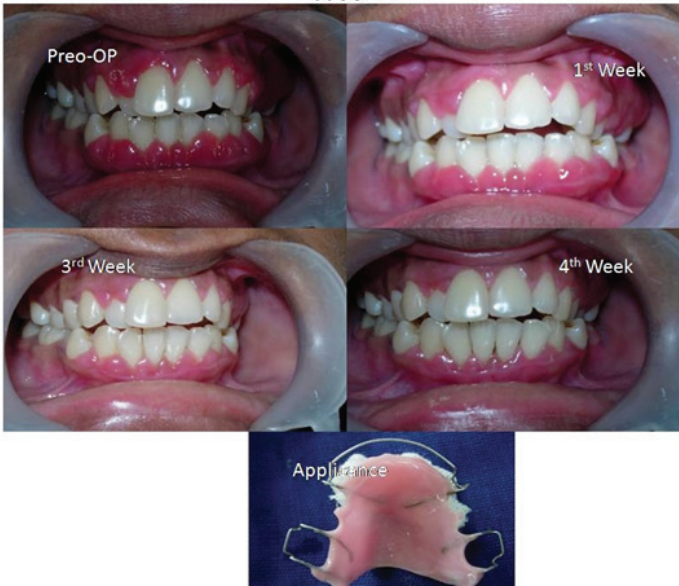

Figure 1: Case No.1-Pre-op photo and Post-op photos after Non-surgical Periodontal Therapy.

Case -2

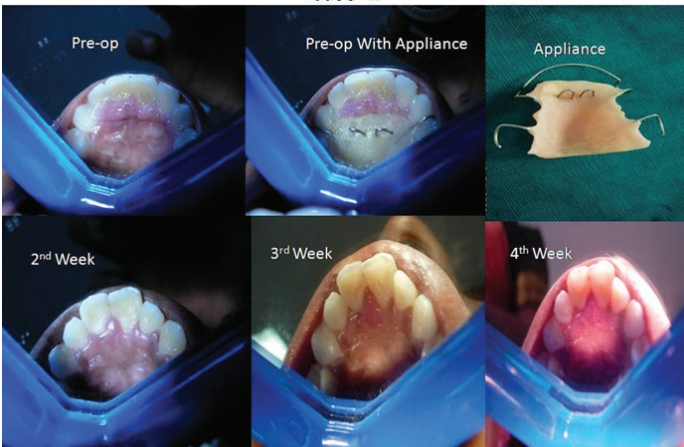


Figure 2: Case No.2- Pre-op photo and Post-op photos after Non-surgical Periodontal Therapy.

Case-3

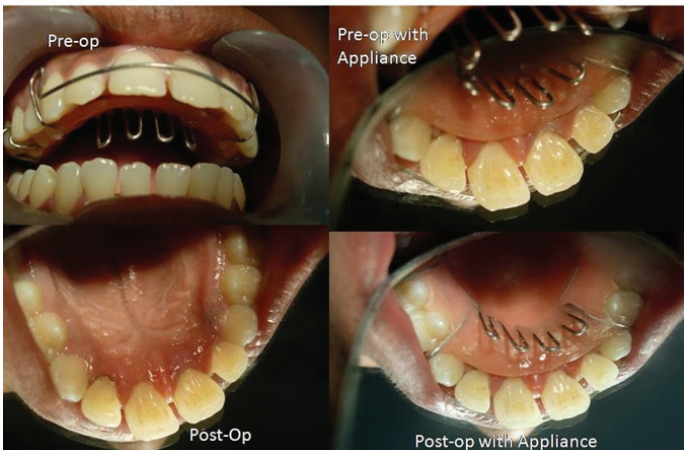


Figure 3: Case No.3- Pre-op photo and Post-op photos after Non-surgical Periodontal Therapy.

Case-4

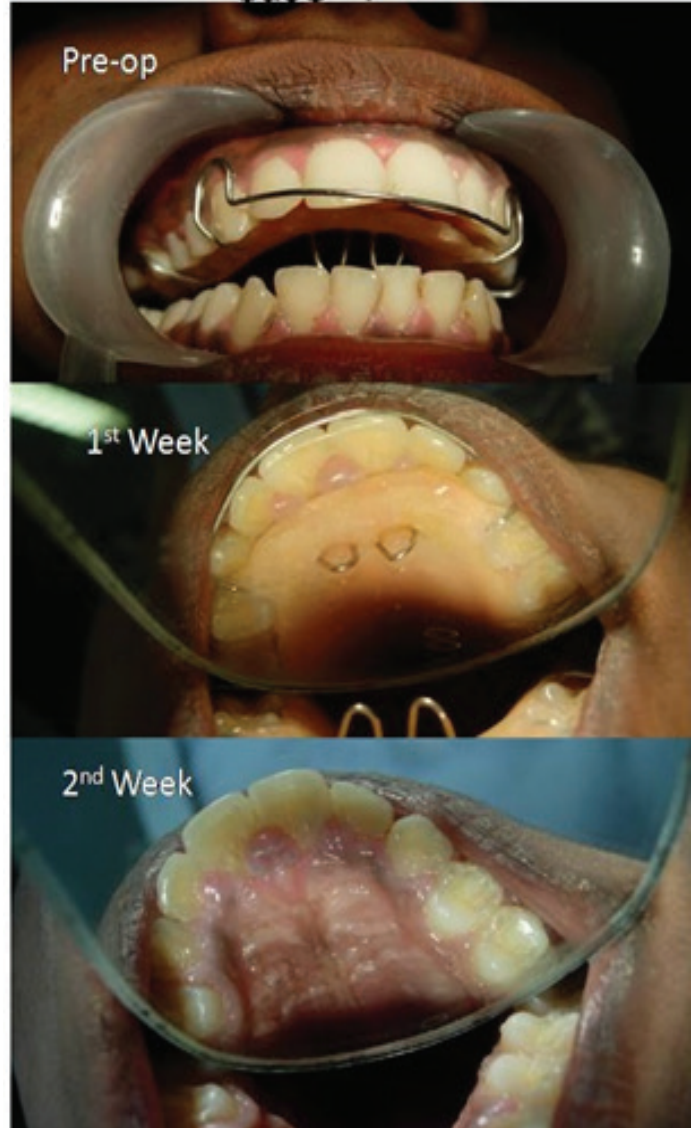

Figure 4: Case No.4- Pre-op photo and Post-op photos after Non-surgical Periodontal Therapy.

Case-5

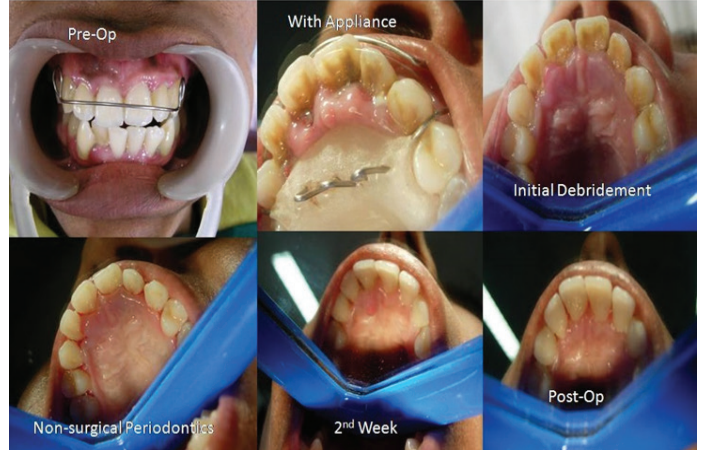

Figure 5: Case No.5- Pre-op photo and Post-op photos after Non-surgical Periodontal Therapy.

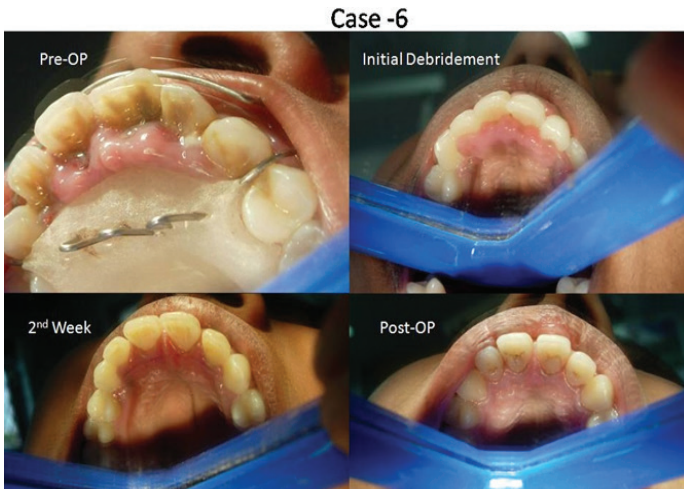

Figure 6: Case No.6- Pre-op photo and Post-op photos after Non-surgical Periodontal Therapy.

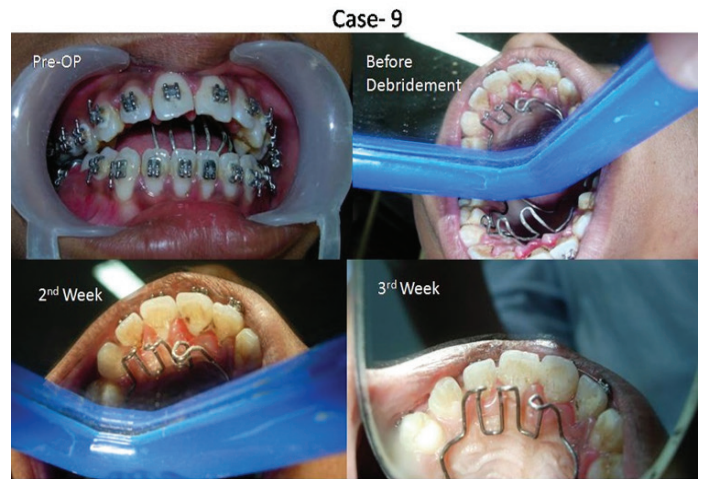

Figure 8: Case No.9- Pre-op photo and Post-op photos after Non-surgical Periodontal Therapy.

Case- 7,8

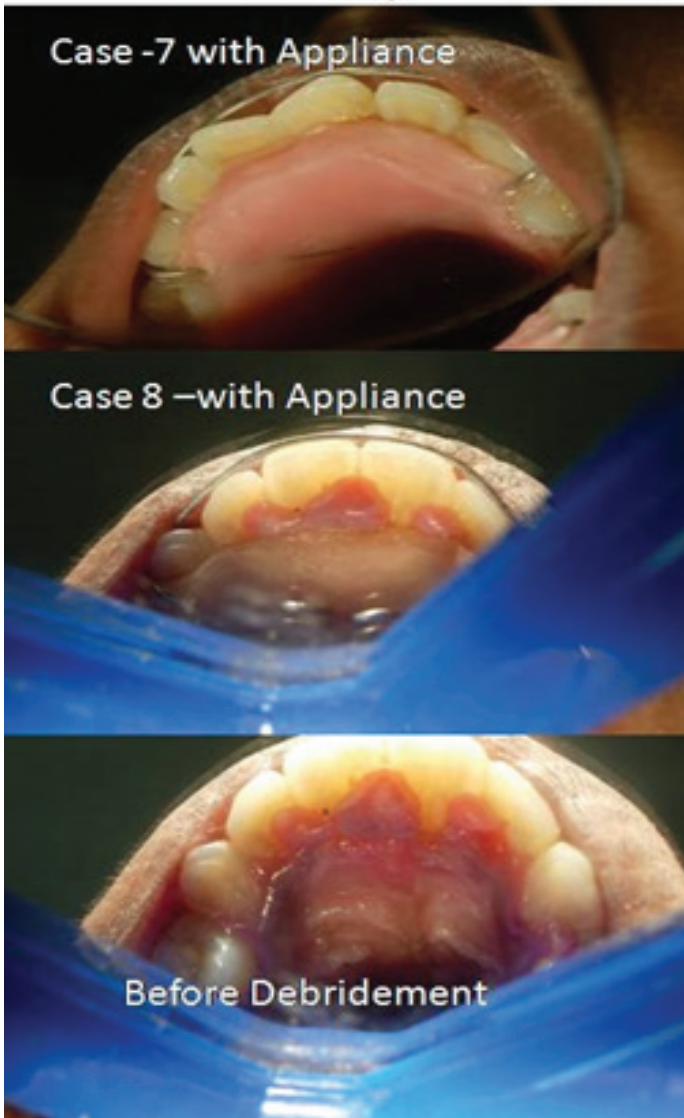


Figure 7: Case No.7 - Pre-op photo and Case No.8- Pre-op and Post-op photos after Non-surgical Periodontal Therapy.

DISCUSSION

Medical error was first reported in the literature in the early 1960's by the pioneering work of Schimmel,⁶ who showed that patients are frequently injured by the same medical care that was intended to help them. The American Quality Interagency Co-ordination Task force defined an error⁷ as "An error is defined as the failure of a planned action to be completed as intended or the use of a wrong plan to achieve an aim. Errors can include problems in practice, products, procedures, and systems." Because medical errors usually affect only a single patient at a time, they are treated as isolated incidents, which explain the paucity of reports. Health care errors are also un-reported due to liability and confidentiality concerns. Contrary to popular expectations doctors, dentists and other health care professionals are indeed fallible and prove the old adage "To Err is Human". The enhancement of patient safety encompasses three complementary activities: preventing errors, making errors visible, and mitigating the effects of errors. Hence it is critical to find out what happened, why it happened, and how it can be prevented in the future.

Also, Medical error may not amount to medical negligence, but in this era of consumer driven healthcare and burgeoning medical knowledge of the general public through easy access to widespread online resources, Iatrogenic errors and the failure to forestall them through adequate developments of skills and knowledge is tantamount to Medical Negligence. Focusing on the specifics of one particular treatment modality without adequately taking care of the overall oral health of the patient is equal to missing the woods for the trees. As reviewed by the previous two studies, the main causative factor for physical iatrogenic trauma to the gingiva is orthodontic appliances and management.^{1,2} The resultant lesion is usually a reactive inflammatory hyperplasia of the gingiva.⁸ Management of such injuries lies basically in removing the insult and instituting a good prophylaxis routine^{9,10} – both patient and Periodontist administered. Such non surgical therapy can be followed if necessary by mucogingival plastic surgery procedures for definitive management.

CONCLUSION

The oral cavity comprises both hard and soft tissues. Focusing on one particular treatment specialty to the exclusion of all else leads to unexpected and contrarian results. Although "To Err is Human" willful neglect is actionable under a court of law and must be kept in mind when

treating any iatrogenic induced gingival lesion, especially by the Periodontist managing the case at a later date and who may be called forth as an expert witness to offer evidence for the suitability of previous therapies. Hence it becomes mandatory for the periodontist who is called to manage these cases to have effective documentation of such cases right from the time of examination to indemnify themselves from being cited as part of these medical negligence cases and to avoid being cited for deficiencies in quality of care in a court of law.

SUMMARY

1. Iatrogenic assault to gingival and periodontium by orthodontic specialists is one of the worst kept secrets in dentistry.
2. The key to successful management of the iatrogenic injuries is to be honest and upfront with the patient regarding the source of the injuries.
3. Any further injury can be prevented by communicating and educating the orthodontist regarding violations of periodontal and gingival tissues and their after math.

CONFLICT OF INTEREST

There is no financial conflict of interest as the study was self-funded and consists of patients who were treated for free by a single surgeon/single author of study.

REFERENCES

1. Onur Ozcelik, M. Cenik Haytac, Murat Akkaya. Iatrogenic Trauma to Oral Tissues. *J Periodontol.* 2005;76(10):1793-7. <http://dx.doi.org/10.1902/jop.2005.76.10.1793>; PMID:16253103.
2. Swati Y. Rawal, Lewis J. Claman, John R. Kalmar, Dimitris N. TAT akis. Traumatic Lesions of the Gingiva : A Case Series.
3. Baer PN, Cocco J. Gingival enlargement coincident with orthodontic therapy. *J Periodontol.* 1964;35(5):436-9. <http://dx.doi.org/10.1902/jop.1964.35.5.436>.
4. Armitage GC. Development of a classification system for periodontal diseases and conditions. *Ann Periodontol.* 1999;4(1):1-6. <http://dx.doi.org/10.1902/annals.1999.4.1.1>; PMID:10863370.
5. Holmstrup P. Non-plaque-induced gingival lesions. *Ann Periodontol* 1999;4(1):20-9 <http://dx.doi.org/10.1902/annals.1999.4.1.20> ; PMID:10863372.
6. Schimmel EM. The hazards of hospitalization. *Ann Intern Med* 1964;60:100-10 <http://dx.doi.org/10.7326/0003-4819-60-1-100> ; PMID:14106730.
7. Report of the Quality Interagency Coordination Task Force (QuIC): Doing what counts for patient safety: Federal actions to reduce medical errors and their impact. February 2000.
8. Zachrisson S, Zachrisson BU. Gingival condition associated with orthodontic treatment. *Angle Orthod.* 1972;42(1):26-34 <http://dx.doi.org/10.3109/00016357209004597>.
9. Davies TM, Shaw WC, Warthington HV, Addy M *et al.* The effect of orthodontic treatment on plaque and gingivitis. *Am J Orthod Dentofacial Orthop.* 1991;99(2):155-61. [http://dx.doi.org/10.1016/0889-5406\(91\)70118-G](http://dx.doi.org/10.1016/0889-5406(91)70118-G).
10. Nikki E. Atack, Jonathan R. Sandy, Martin Addy. Periodontal and Microbiological Changes Associated With the Placement of Orthodontic Appliances. A Review *J Periodontol.* 1996;67(2):78-85. <http://dx.doi.org/10.1902/jop.1996.67.2.78>; PMID:8667140.

Cite this article : Ganesh PR. Iatrogenic trauma to Gingiva – A Case Series. *BEMS Reports*, 2016; 2(1): 23-6.